

THE MUSCULOSKELETAL 
SCREENING EXAMINATION

JOHN M. THOMPSON MD FRCPC
AND AINSLEY WALTON

Contents

Introduction	p.1
Patient Standing	p.3
Patient Sitting	p.12
Patient Lying	p.26

Written By

John M.Thompson MD FRCPC
Division of Rheumatology
Department of Medicine
Faculty of Medicine
University of Western Ontario

St. Joseph's Hospital
268 Grosvenor Street
London, Ontario N6A 4V2

Illustrated By

Ainsley S.Walton

©1998 by John M.Thompson

Unauthorized duplication of these materials is strictly prohibited.

THE SCREENING MUSCULOSKELETAL EXAMINATION

This rapid, systematic “once-over” is organized to detect deviations from the normal. If any are found, they can be more closely scrutinized through joint-specific examination.

There is no “gold standard” screening examination — but this is one that most physicians would agree is reasonably comprehensive.

This examination can be carried out quickly. Once mastered, it should take less than 5 minutes, and can be integrated smoothly into the general physical examination.

The order described here — the patient standing, then sitting, then lying supine — differs from the sequence “sitting - lying - standing” preferred by many. However, by placing the “standing” component first, lower extremity abnormalities that may be obvious only on weight-bearing can be detected. Joints so singled out can then be subject to close attention when the patient is lying.

BASIC PRINCIPLES

Humans are bilaterally symmetrical. As the examiner moves from one area to another, one side is compared not just to an ideal “normal”, but to the other side.

Observation and comparison, as each area is examined in sequence, is particularly useful in determining if there are abnormalities of

- alignment of one bone on another
- muscle bulk
- joint swelling
- the range of motion the patient can carry out (this is termed “active movement”)

Palpation adds specific information regarding

- joint warmth — usually signifying inflammation
- joint tenderness
- joint effusion — indicating the presence of fluid within the joint
- crepitus — palpable or audible “grinding” as a joint is moved. Crepitus may be bony, cartilaginous, or synovial.
- joint instability
- restricted range— here the examiner attempts to take the joint through its normal range (“passive movement”) and compares this to the active range

**PATIENT
PREPARATION**

The patient should remove all but underclothing. A gown, tied at the back of the neck, allows for both warmth and modesty. When the shoulders are being examined, the arms may be slipped out of the sleeves. A woman may tuck the gown into the top of her bra. Listed, in sequence, is a rational order of examination. For each step there is a suggested verbal command. It is often effective, however, to show, as well as tell, the patient what is wanted. Thus, when assessing shoulder abduction and external rotation, instruction is combined with demonstration — “put your hands behind your head *like this* — now elbows way back *like this* — and stick out your chest *like this*.”

SEQUENCE OF EXAMINATION

**PATIENT
STANDING**

- assessment modality: active movement
- integrate with lower body neurological assessment, especially muscle strength

**PATIENT
SITTING**

- assessment modality: both active and passive movement
- integrate with vital signs, head and neck, thorax, neurological

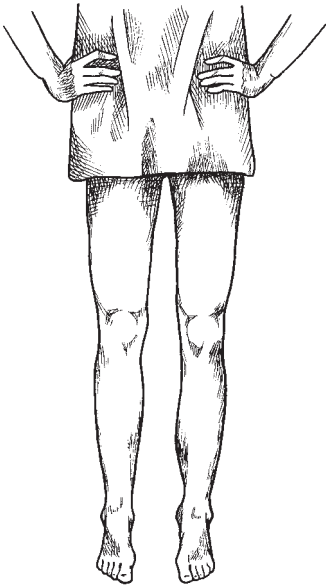
**PATIENT
LYING**

- assessment modality: passive movement
- integrate with cardiovascular, abdomen, genitalia, nodes

STEP 1.

Inspect the patient from the front

Direction: “raise your gown to mid-thigh, and stand with your feet slightly apart facing me.”



Observe:

- ◀ thigh muscle mass, symmetry
- ◀ knee alignment
- ◀ knee swelling
- ◀ ankle alignment
- ◀ ankle swelling
- ◀ longitudinal arch
- ◀ toe alignment
- ◀ toe swelling

Comment:

- quadriceps wasting often accompanies knee arthritis
- “bow-leg” = genu varus
- “knock-knee” = genu valgus
- hyperextension = genu recurvatum
- look for suprapatellar bulging, filling in of medial and lateral parapatellar “gutters”
- neutral, varus, valgus
- malleoli should be sharply defined
- “flat foot” = pes planus
- “bunion” = hallux valgus
- “hammer toes”
- “claw toes”
- “sausage toe” = dactylitis

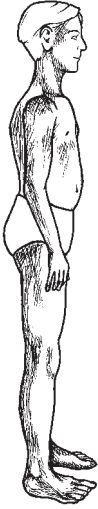The fine print:

- Knee varus or valgus may be normal for an individual. It may also result from arthritic change in either the medial tibiofemoral compartment (causing varus) or lateral tibiofemoral compartment (causing valgus).
- Knee valgus is often linked to patellofemoral pain, and crepitus, presumably because the angulation leads to abnormal gliding of the patella between the femoral condyles as the knee moves through flexion and extension.
- Genu recurvatum (that is, the knees hyperextend past 180°) is particularly common in young women. It may be part of a general tendency to joint hypermobility. Elbows, fingers, and thumbs may also bend backwards. Such an individual may be able to place, with knees straight, palms flat on the floor. Such hypermobility may be a source of joint pain.
- Dactylitis of a toe (or a finger) is most commonly seen in psoriatic arthritis. The swelling is usually red or purplish in colour and can be mistaken for infection.

STEP 2.

Observe the patient from behind

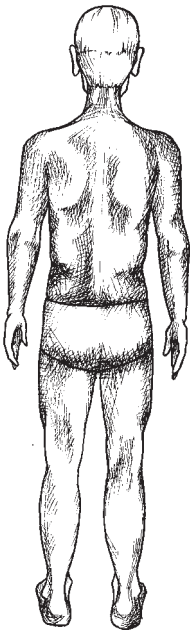
Direction: “Now turn around so that I can look at your spine”



Observe:

Comment:

- | | |
|---|---|
| <ul style="list-style-type: none"> ◀ spinal curves in sagittal plane | <ul style="list-style-type: none"> ■ cervical lordosis ■ dorsal kyphosis ■ lumbar lordosis |
|---|---|



Observe:

Comment:

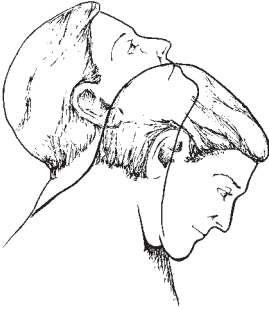- | | |
|--|---|
| <ul style="list-style-type: none"> ◀ spinal curve in coronal plane ◀ waist skin creases ◀ thigh muscle bulk & symmetry ◀ popliteal fossa (back of knee) ◀ calf muscle bulk & symmetry ◀ ankle alignment ◀ Achilles tendon, malleoli | <ul style="list-style-type: none"> ■ normal (occiput over midsacrum) or ■ scoliosis ■ asymmetry may indicate scoliosis or leg length discrepancy ■ asymmetrical fullness may indicate a Baker's cyst ■ neutral, varus, valgus ■ should be sharply sculpted |
|--|---|

The fine print:

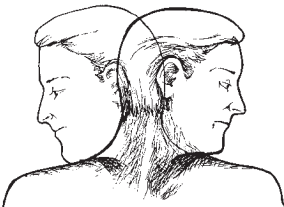
- Scoliosis may be more obvious when the patient demonstrates forward flexion (step 3)
- A difference in leg length, either actual or factitious (due to incomplete extension of either the hip or knee) may be assessed by palpating the iliac crests in the mid-axillary line. With an index finger on each side, look to see if they line up horizontally, or if there is a pelvic tilt.
- In roughly a third of all patients, a communication exists between the knee joint space and the popliteal bursa. In the presence of a knee effusion, joint fluid will drain from the high pressure knee to low pressure bursa, resulting in bursal swelling (a Baker's cyst). If the swelling comes on rapidly, the bursa may rupture, with calf pain and ankle bruising, simulating a deep vein thrombosis of the calf. If the swelling is chronic, it may expand into the calf beneath the gastrocnemius, causing calf asymmetry.
- A unilaterally thickened Achilles tendon, often red and tender, is a hallmark of seronegative arthritis.
- The normal concavity beneath the malleoli may be "filled in" in the case of tenosynovitis involving the posterior tibial tendon (medially) or peroneus longus tendon (laterally)

STEP 3.*Observe spinal movement*

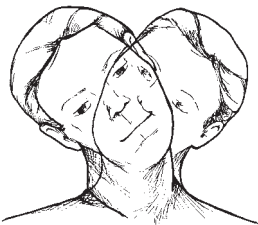
Cervical spine: *Gently touch the right or left acromioclavicular joint with your finger as instructions for rotation and lateral flexion are given. DO NOT attempt to push the patient's head through the desired range.*

**Direction:****Movement:**

-
- ◀ “look at the ceiling” ■ extension
 - ◀ “touch your chin to your chest” ■ flexion

**Direction:****Movement:**

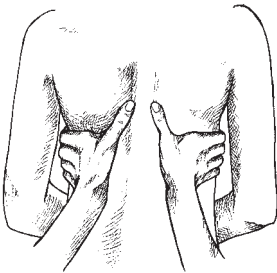
-
- ◀ “touch your chin to each shoulder” ■ rotation

**Direction:****Movement:**

-
- ◀ “now touch your ear to each shoulder” ■ lateral flexion

**Thoracic:
(costovertebral)**

Make a caliper of your two hands, encircling the chest just below the scapulae, thumbs touching in the midline. As the patient breathes in and out deeply, assess both symmetry and range of chest movement.



Direction:

◀ “ take a deep breath and let it out”

Movement:

■ chest expansion

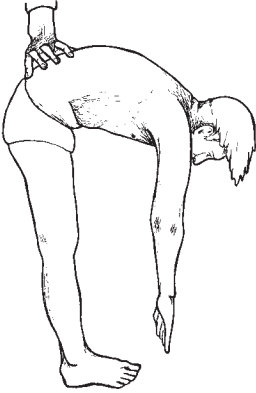The fine print:

- Chest expansion may be symmetrically limited in patients with emphysema, whose lungs are chronically hyperinflated, or in those with ankylosing spondylitis, where free movement of costovertebral joints may be severely restricted. To document this, a tape is placed about the thorax at the level of the nipples, and measurements taken at full inspiration and expiration. It should be at least 2 cm (4-5 cm of excursion is usual).
- Asymmetric limitation of expansion usually indicates intra-thoracic disease (such as a large unilateral pleural effusion).

STEP 3. CONTINUED

Observe spinal movement

Lumbar spine: *Align right hand finger tips in the lumbar lordotic curve, and note the degree of finger separation with forward flexion.*



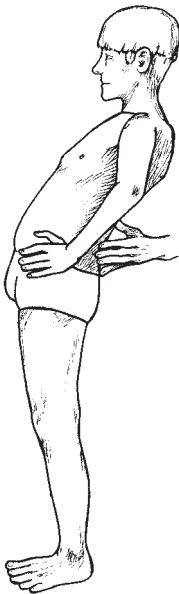
Direction:

Movement:

◀ “knees straight, try to touch your toes”

■ flexion

Align spread finger tips in the lumbar lordotic curve, gently supporting the patient, and note extent to which finger tips come together.



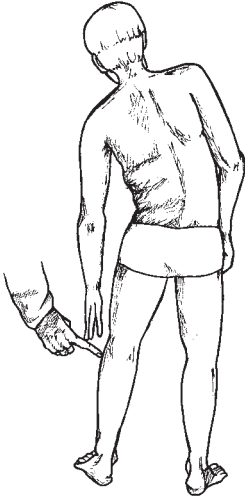
Direction:

Movement:

◀ “hands on hips, lean way back”

■ extension

Patient tries to touch examiner's finger, which is placed on head of fibula.



Direction:

- ◀ “knees straight, tip sideways to touch my finger”

Movement:

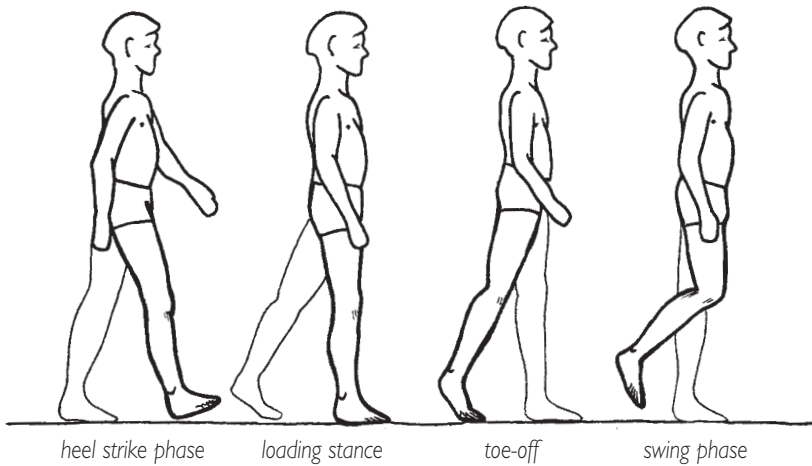
- lateral flexion

The fine print:

- As lumbar flexion is carried out, the normal lordotic curve flattens to neutral, then reverses in kyphosis. Pain experienced with flexion may reflect lumbar disc disease.
- The Schober test is a measurement of spinal flexion which can be used to monitor improvement or deterioration in ankylosing spondylitis. One variant of this test consists of placing a mark over the lumbar spine at the level of the dimples of Venus while the patient is erect in the neutral position. Two other marks are made, one 10 cm above and one 5 cm below the original mark. The patient then bends forward as far as possible. The distance between the marks is re-measured, and should be at least 20 cm.
- Restricted lumbar extension, with discomfort, is common and is felt to reflect facet joint arthritis.
- Lumbar spine movement, including lateral flexion, is commonly restricted in ankylosing spondylitis

STEP 4.*Observe patient walking*

Direction: “now walk away from me, turn around, and walk back”

**Compare one side with the other:**

- ◀ “swing” phase —
when the foot swings forward after push-off
- ◀ “stance” phase —
from heel-strike through flat foot contact to toe push-off

Once the patient has taken three steps, the gait pattern is established. There is a lot to watch – the lumbar spine, pelvis, hips, knees, ankles, and feet. Compare the timing and duration of stance phase on each side; check to see if stride lengths are equal. Look from front and back and, if necessary, the side.

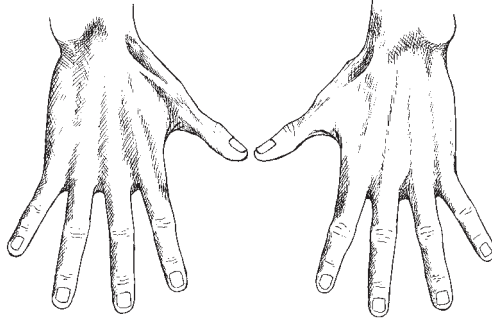
The fine print:

- The antalgic (antalgic = “against pain”) gait may reflect a painful focus anywhere from the foot up to the pelvis. The patient attempts to “unload” the painful side. Consequently, the stance phase on that side is briefer, and the swing phase on the opposite (normal) side is shorter – making for a shorter stride.
- The arthrogenic (stiff knee or hip) gait is a consequence of joint stiffness, and is not necessarily painful. Because there is a limited hip/knee flexion on the affected side, there is exaggerated foot plantar flexion on the “good” side (the patient goes up higher on the toes), whereas the “bad” leg is circumducted during the swing phase to allow toe clearance.
- Trendelenburg’s Gait results from unilateral hip abductor muscle dysfunction. This may be a consequence of neurological weakness, or of hip joint dysfunction (e.g. hip osteoarthritis) that would be aggravated by adductor contraction (which can double the weight-bearing load on that hip). There are two components to the Trendelenburg gait. The thorax is thrust laterally to place the center of gravity over the “bad” leg during the stance phase, and simultaneously the pelvis sags on the contralateral side (because the ipsilateral hip adductors do not contract to hold the pelvis level).

STEP I.

Inspect the dorsum of the hands and test finger extension

Direction: “show me the backs of your hands — spread your fingers as far as possible”

**Observe:**

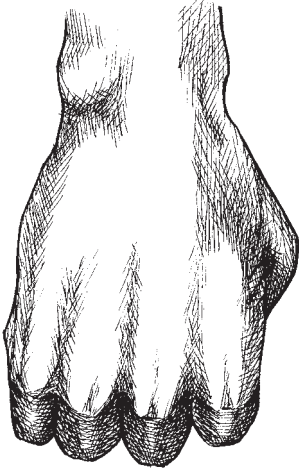
- ◀ wrist bony landmarks
- ◀ finger alignment
- ◀ contours of MCP, PIP, DIP joints
- ◀ skin colour over knuckles
- ◀ fingernails
- ◀ skin of fingers

Comment:

- ulnar styloid visible or lost in soft tissue swelling
- straight, without ulnar or radial deviation
- evidence of soft tissue or bony enlargement
- reddened
- clubbing, pitting, nail fold vasculitis, onycholysis
- shiny, taut, swollen, or normally wrinkled

The fine print:

- Ulnar deviation of the fingers, due to rheumatoid arthritis, occurs only after several years of active disease.
- If the fingers cannot be fully extended, there is probably a finger flexion contracture. This can be confirmed by the “prayer sign” — ask the patient to oppose palms and digits as if praying. There should be no visible gap between palmar surfaces of the fingers.
- The most common cause of enlargement of the DIP joint is nodal osteoarthritis. These bony bumps are known as Heberden’s nodes (their counterparts in the PIP joints are known as Bouchard’s nodes). Early in their development they may be quite tender and even inflamed, but not as inflamed as the swollen, red, tender DIP joints seen in some patients with psoriatic arthritis.
- Redness of knuckles, denoting inflammation, is seldom seen in the commonest form of inflammatory arthritis, rheumatoid arthritis — but it is a feature of gouty arthritis, infection, psoriatic arthritis, and even in some cases of nodal osteoarthritis (see above).
- Clubbing may be a clue to an underlying malignancy or endocarditis. Pitting of the fingernails, or separation of the nail from the underlying tissue (onycholysis), may provide the essential clue to a diagnosis of psoriatic arthritis. Nail fold vasculitis is seen in lupus and rheumatoid arthritis.
- Taut skin over the fingers may be a clue to scleroderma.

STEP 2.*Assess MCP joint flexion***Direction:** “Make a fist”**Observe:**

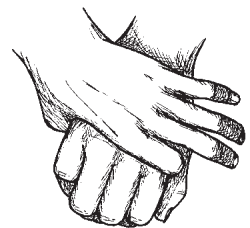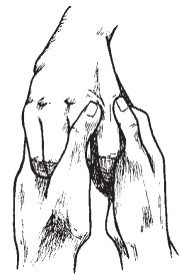
- ◀ knuckles flex to almost 90°
- ◀ troughs between MCPs are concave

Comment:

- “filled in” troughs may be due to subcutaneous tissue (“pudgy hands”) or to MCP joint capsular distension.

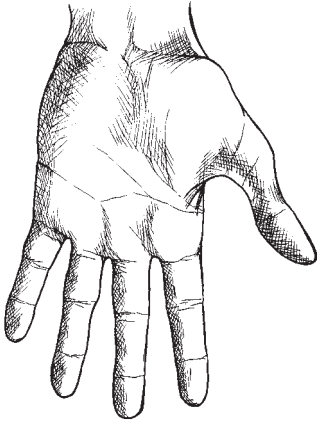
The fine print:

- Inflammation of the MCP joints, evidenced by capsular distension, is one of the hallmarks of rheumatoid arthritis. If suspected, the MCP joints should be palpated, using both thumbs (see illustration). Try to feel the joint lines.
- A quick “screen” for MCP arthritis is the manoeuvre shown (compression of the MCPs from the side). A similar “screen” is carried out on the MTP joints of the feet.



STEP 3.
Inspect the palm

Direction: “Now open your fingers”



Observe:

Comment:

- | | |
|---|--|
| <ul style="list-style-type: none"> ◀ thenar and hypothenar eminences ◀ ulnar border of the palm ◀ puckering, nodular thickening ◀ palms fully supinated | <ul style="list-style-type: none"> ■ loss of thenar muscle mass may indicate chronic median nerve pressure in the carpal tunnel ■ ulnar nerve damage may cause wasting of the abductor digiti minimi ■ Dupuytren's contracture (subcutaneous fibrotic thickening) most commonly involves 4th and 5th digits, leading to digital flexion deformity ■ failure may be a clue to elbow arthritis |
|---|--|

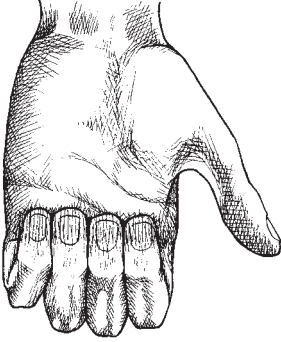
The fine print:

- Pressure on the median nerve in the carpal tunnel has many causes, including wrist synovitis. The “pins and needles” of median nerve compression may be diagnostically reproduced by the Tinel Test (firm percussion with a finger tip or a reflex hammer at the level of the distal crease on the volar wrist) or Phalen’s manoeuvre (the patient is asked to press the backs of the hands together, wrists at 90° flexion) held for 45 to 60 seconds.

STEP 4.

Assess interphalangeal (PIP, DIP) joint flexion

Direction: “Now turn your hand over and tuck your fingers into your palm”

**Observe:**

◀ finger tips touch palm overlying metacarpal heads

Comment:

■ failure may imply either IP joint or flexor tendon dysfunction

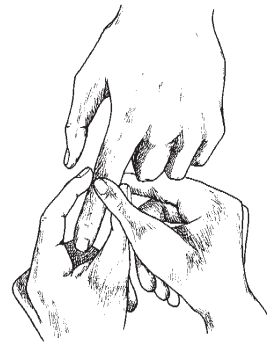
The fine print:

- To distinguish between IP joint effusion and flexor tendon dysfunction:

(1) Palpate the IP joint for capsular distension or bony enlargement. Apply firm pressure with thumb and finger of one hand from above and below, while simultaneously using the thumb and finger of the other hand to press firmly at the joint line, feeling for the “bounce” of a joint capsule under tension. This skill is of prime importance in detecting evidence of early inflammatory arthritis.

and

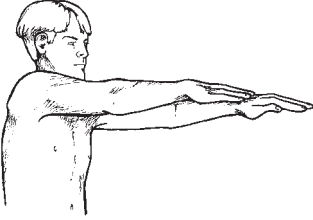
(2) Palpate the flexor tendon. Ask the patient if the finger ever “triggers” (gets “stuck” on attempted closing or opening, suddenly releasing with continued effort with a painful snap). Feel for a nodule in the flexor tendon, particularly just proximal to the metacarpal head, as the finger is both actively and passively flexed.



STEP 5.

Assess arm forward flexion, pronation, then wrist flexion, extension

Direction: “Hands out straight — now bend your wrist straight down, then as far back as possible”

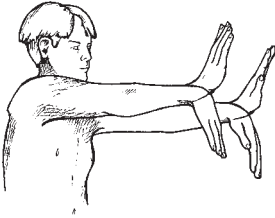


Observe:

◀ contour of dorsum of wrist

Comment:

- subluxation of wrist is a late consequence of rheumatoid arthritis
- wrist joint synovitis or extensor tendon synovitis in RA may “heap up”, particularly with full extension



Palpate:

◀ for increased joint warmth

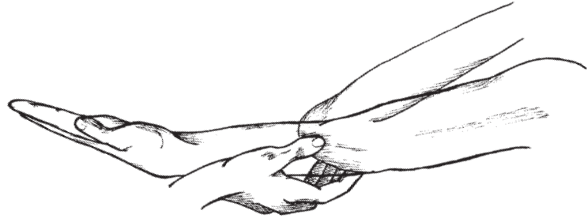
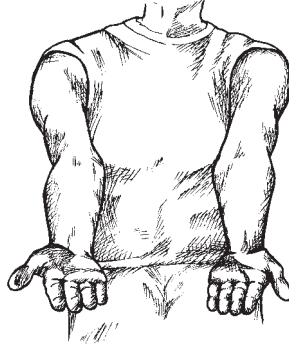- with the wrist in the neutral position, run the back of your hand from mid-forearm across palmar and dorsal wrist, feeling for evidence of inflammation

STEP 6.

Assess elbow supination and extension, then elbow flexion and extension

Direction:

“Now turn your palms up, elbows out straight”
“I’m going to gently move your arm all the way up, then all the way out”



gently place the index finger and thumb of one hand in the “gutters” on either side of the olecranon, and with the other hand grasp the supinated forearm just proximal to the wrist and take the elbow through a full range of flexion/extension

Observe:

- ◀ palm fully supinates to horizontal
- ◀ degree of valgus deviation at elbow
- ◀ flexion so forearm meets biceps
- ◀ both elbows extend at least to neutral

Comment:

- failure to fully supinate may be subtle sign of elbow dysfunction
- elbow valgus greater in women than men
- women (and those with hypermobility) commonly hyperextend 10-15°

Palpate:

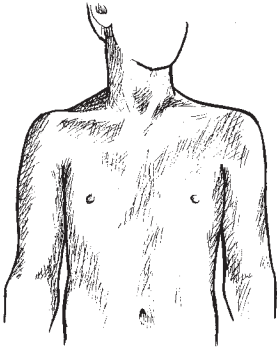
- ◀ feel for crepitus as the joint moves

The fine print:

- Feel for “bulging” of elbow joint capsule with index finger/thumb tips, particularly as full extension/flexion is approached. Full extension may be inhibited by elbow inflammation, and capsular bulging may betray it.
- At the end of this elbow assessment, quickly palpate the extensor surface of the forearm over the tip of the olecranon and the 3 to 4 cm just distal to it — this is where a thickened or swollen olecranon bursa and rheumatoid nodules may be felt.
- “Tennis elbow” and “golfer’s elbow” are common causes of elbow pain. Firm pressure over the lateral and medial epicondyles of the elbow (respectively) may elicit pain. Indirect stressing of the lateral entheses (entheses = site of attachment of ligament/tendon to bone) is a useful diagnostic test for a “tennis elbow”. Ask the patient to keep the wrist in extension while you attempt, by pressure on the dorsum of the hand, to force it into the neutral position. Pain over the lateral epicondyle constitutes a positive test. Attempts to overcome active flexion of the wrist may provoke the pain of a “golfer’s elbow”, or medial epicondylitis.

STEP 7.*Inspect the shoulders*

this is done with clavicles, shoulders, scapulae fully exposed (see “Patient Preparation”). Compare one side with the other, front and back.

**Observe:**

- ◀ compare shoulder contours from the front
- ◀ compare alignment of clavicles, symmetry of prominence of sternoclavicular and acromioclavicular joints
- ◀ compare scapulae from behind (have patient cross arms in front of chest to bring scapulae into prominence)

Comment:

- dominant side may be more muscled, lower than non-dominant side
- deltoid muscle wasting due to shoulder arthritis may “square off” the normal contour
- supraspinatus wasting occurs with rotator cuff or glenohumeral disease

The fine print:

- Palpation, particularly to elicit pain and/or crepitus in patients with shoulder pain, can be added to observation, and takes very little additional time.
- Both the sternoclavicular and acromioclavicular joints may be checked for pain and palpable crepitus by asking the patient to shrug while the respective joints are firmly palpated. Using the tips of the fingers of each hand, each pair can be assessed at the same time.
- The bicipital tendon, located in the bicipital groove between the greater and lesser tuberosities, can be palpated for tenderness, as can the subdeltoid bursa (an extension of the subacromial bursa) in the groove at the tip of the acromion.

STEP 8.

Observe shoulder range of motion (active)

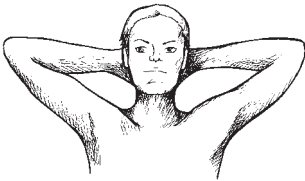
Movements should be smooth, symmetrical, and simultaneous



Abduction Direction:

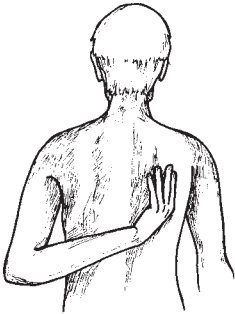
- ◀ “Bring your arms from your side straight overhead, palms touching; now bring them slowly down to your side again.”

External rotation Direction:



- ◀ “Put your hands behind your head, bring elbows way back, and stick out your chest”

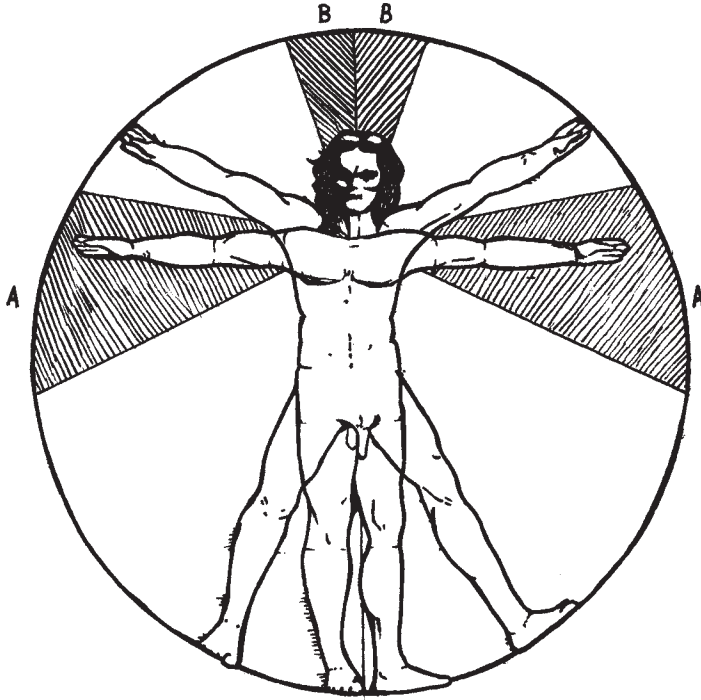
Internal rotation (and extension) Direction:



- ◀ “Now put one hand behind your back and touch the opposite shoulder blade. Now do the same with the other hand”

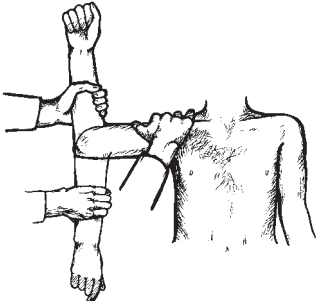
The fine print:

- If the patient experiences pain at the mid-range of abduction (arc "A"), its origin is likely subacromial (e.g. supraspinatus tendon, subacromial bursa). Shoulder pain in the last 10-15° of abduction (arc "B") is more likely to arise from the acromioclavicular joint.



STEP 9.

Compare passive shoulder range of motion with active range of motion



Facing the patient, and assessing the right shoulder, place your right hand over the patient's right trapezius, fingers firmly pressing the supraspinatus muscle. With your left hand, gently grasp the forearm just below the elbow and raise (abduct) the arm in the coronal plane. Continue to abduct until you feel the scapula begin to rotate under your restraining hand.

Next, gently externally rotate the arm, the elbow bent at 90°, until pain or tissue resistance calls a halt to the manoeuvre. Reverse the movement, assessing internal rotation, the arm still fully abducted, elbow bent, until the forearm movement is arrested.

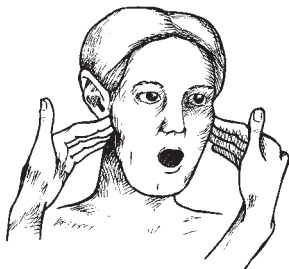
The fine print:

- Pain and impairment of movement when the patient carries out the movement (active), but which is absent when the examiner takes the joint through the same range (passive), suggests a soft tissue problem (e.g. tendinitis).
- Significant pain and restriction with both active and passive movement points to the glenohumeral joint.
- In the case of a “frozen shoulder”, end-range discomfort is present, but the major impression is that of severely restricted movement in all planes.
- Passive movement of the shoulder (the examiner does the moving) can also be carried out from behind, with the left hand (when the right shoulder is being assessed) fixing the angle of the scapula against rotation, and the right hand grasping the arm just above the elbow. The elbow is then lifted to the end point of scapular movement (normally 90°). The forearm, hanging straight down in “scarecrow” position (full internal rotation) is then pivoted to the vertical with the fingers of the right hand (full external rotation).

STEP 10.

Assess temporomandibular joint movement

Direction: “open and close your mouth”



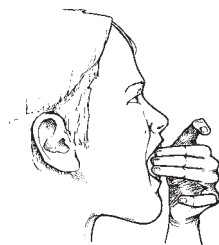
palpate both temporomandibular joints with the index and long fingers of each hand (alternatively, gently place index finger tips in the external ear canals with mild forward pressure).

observe the central incisors of the mandible for any deviation from the midline

observe that the upper incisors just overlap the lower incisors

The fine print:

- In the case of a TMJ arthritis there may be crepitus and tenderness elicited as the jaw moves. The central incisors may initially deviate toward the painful side.
- Childhood arthritis may result in growth restriction of the mandible (“micrognathia”) with a marked overbite
- Patients with TMJ arthritis, and patients with scleroderma, may have marked restriction and be unable to pass the “three finger test”. If such restriction is suspected, ask the patient to attempt to place three fingers, vertically, between the upper and lower teeth (see illustration)

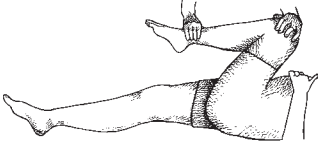


STEP I.

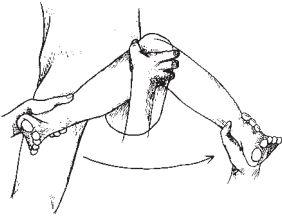
*Hip flexion, internal rotation, & external rotation
Knee flexion, extension*

Direction:

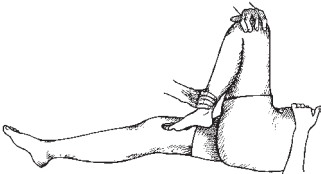
“now I’m going to bend your knee up to your chest, then twist your leg in and out”



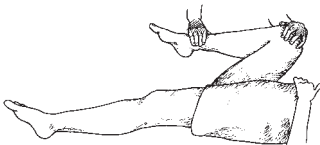
Gently place one hand over the patella and with the other gently grasp just above the ankle. Guide the hip into full flexion (almost to chest), then take it back into 90° of flexion.



Gently guide the hip through the full range of internal rotation (heel out), followed by external rotation (heel in).



Now rotate the hip joint back into the neutral position and guide the leg into full knee flexion. The heel should almost touch the buttock.



Bring the leg down into full extension. No gap should appear behind knee. Repeat with the other leg, and compare.

The fine print:

- Watch the opposite leg when assessing full hip flexion. If it lifts off the examining table, there is probably a flexion contracture on that side.
- The earliest finding in hip disease is usually restriction of internal rotation (in the shoulder, it is usually restriction of external rotation).
- By palpating the patella as the range is assessed passively, knee joint crepitus may be detected. If the patello-femoral articulation is the culprit, this may be confirmed by grasping the patella and moving it side-to-side — you may feel crepitus and the patient may show, in facial expression, displeasure (the “apprehension sign”).
- If there appears to be quadriceps muscle bulk asymmetry (common in knee arthritis), mark the skin on each leg a fixed distance above the upper patellar poles (e.g. 6 cm), measure the circumference and compare the two sides
- A rough assessment of leg length inequality may be made by measuring each leg from anterior superior iliac spine to medial malleolus (you can also check to see how the heels line up with the legs fully extended on the examining table).

STEP 2.

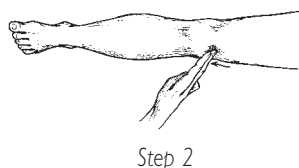
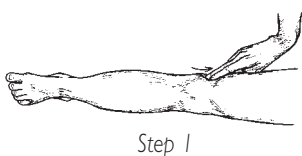
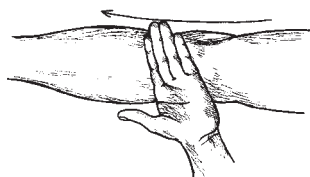
Assess for knee effusion

Observe:

- ◀ repeat observations for suprapatellar bulging, filling in of parapatellar “gutters”

Feel:

- check for increased warmth over the patella — run the back of your hand from distal thigh over patella to proximal shin. The normal sequence is “warm — cool — warm”. All inflammatory effusions (and some in non-inflammatory conditions as well) will be betrayed by the loss of normal pre-patellar coolness.



Test for a small effusion:

- ◀ very small effusions can be pushed from one side of the knee to the other (the “bulge” sign). A single firm sweep up the inner patellofemoral “gutter” (Step 1) is followed by a single firm sweep down (Step 2) the outer patellofemoral “gutter”. Take care not to displace the patella medially. Look for a “bulge” on the inner knee after a second’s delay.

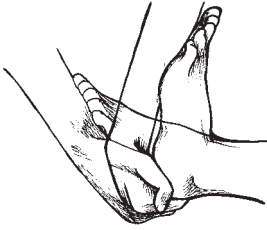
The fine print:

- Effusions may be very difficult to detect in individuals with “fat” knees, and prepatellar warmth may be the only clue.
- The “patellar tap” test is a manoeuvre designed to detect larger effusions — those that have caused the patella to float up out of its normal position of rest in the groove between the femoral condyles. The examiner, placing the tips of one or more fingers of the right hand securely on the patella, thrusts firmly downward toward the intercondylar groove. Patellar movement is estimated. Normally, there is none. If a knee effusion is present, downward movement may be detected, and arrested with a palpable “tap” or click. More often, however, even though movement is detected, the “tap” is absent. You may try to augment this test by compressing the suprapatellar pouch with the palm of your left hand while attempting the “tap” with your right.

III PATIENT LYING

STEP 3.

Assess ankle dorsiflexion and plantar flexion

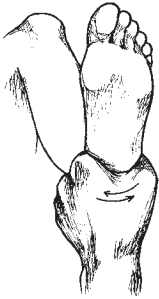


each heel (calcaneus) can be cupped, in turn, in the palm of the hand. With gentle pressure from the volar wrist the foot can be brought up into full dorsiflexion (about 15° past neutral), then into full plantar flexion (approximately 55°) below neutral.

III PATIENT LYING

STEP 4.

Assess subtalar movement (inversion & eversion)



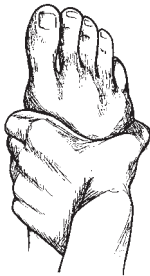grasp the calcaneus and, with the foot pressed up into full dorsiflexion (to lock the talus in the ankle mortice), gently exert inward pressure on the calcaneus followed by outward pressure.

Subtalar arthritis is a common source of hindfoot pain, and this manoeuvre may bring it out.

III PATIENT LYING

STEP 5.

Screen for MTP pain



with one hand, gently but firmly exert a sideways compressive force on the MTP's of each foot. If pain is elicited, palpate, between thumb and forefinger, the individual MTPs to determine the specific painful site.

Dedicated To

Hugh Little MD FRCPC
mentor, colleague and friend

**The Financial assistance of
The Arcangelo Rea Family Foundation**
is gratefully acknowledged

Supported by an educational grant
from Pfizer Canada Inc.

Thanks to

Karen and John Hueston of the Aylmer Express
Anne Lyddiatt
and my colleagues in the Division of Rheumatology

SCREENING CHECKLIST

- Standing:**
- inspect from front
 - inspect from behind
 - cervical spine extension, flexion, rotation, lateral flexion
 - chest expansion (costovertebral movement)
 - lumbar flexion, extension, lateral flexion
 - observe gait
-

- Sitting:**
- inspect dorsum of hands, finger extension
 - MCP flexion
 - PIP, DIP flexion
 - inspect palms
 - arm forward flexion, pronation
 - wrist flexion, extension
 - forearm supination, elbow extension
 - elbow flexion, extension
 - inspect shoulders
 - observe active shoulder abduction, external rotation, internal rotation
 - compare passive shoulder abduction, external & internal rotation
 - assess temporomandibular joint movement
-

- Lying:**
- hip flexion, internal rotation, external rotation
 - knee flexion & extension
 - assess for knee effusion
 - ankle dorsiflexion & plantar flexion
 - assess subtalar inversion and eversion
 - screen for MTP pain